

ROMUALDA WOJCZYS, WIKTOR BEDNARZ, JANUSZ DAWISKIBA, GRZEGORZ BIELICKI

Colonic Carcinogenesis in an Experimental Model of Chronic Colitis in Rats

Proces karcynogenezy w doświadczalnym modelu przewlekłego zapalenia okrężnicy u szczurów

1st Department of General, Gastroenterological, and Endocrine Surgery, Silesian Piasts University of Medicine in Wrocław, Poland

Abstract

Background. The study of the adenoma-carcinoma sequence in an animal model of chronic colitis resembling human ulcerative colitis is essential to understand the pathogenesis of the process and to allow the testing cancer chemopreventive agents.

Objectives. The aim was to establish a model of chronic colitis to study the relationship between inflammation and cancer development as well as to elucidate the adenoma-to-carcinoma cascade demonstrated by the p53 and Ki67 markers and dysplastic lesions (high and low grade). Additionally, the metastatic affection of liver tissue was investigated.

Material and Methods. An experimental model of colitis and carcinogenesis in 50 two-month-old Wistar rats was used. First colitis was induced using acetic acid and histologically proved, then carcinogenesis in two groups of animals (healthy and with induced colitis) was studied. Azoxymethane was used as the carcinogen.

Results. Colonic adenocarcinoma developed in 30% of the colitis-induced group and in 20% of the group without induced colitis but receiving the carcinogen. Dysplasia preceded the development of colonic adenocarcinoma. Ki67 and p53 positivity was an early sign of colonic malignancy in both dysplastic (mostly high grade) and carcinoma lesions. Liver tissue was affected by metastatic carcinoma only in those animals with chronic colitis.

Conclusions. Chronic colitis resembling human ulcerative colitis leads to the development of colonic adenocarcinoma. In the colitis-induced group the process of carcinogenesis was more frequent and expansive than in the healthy animals (*Adv Clin Exp Med* 2006, 15, 6, 983–988).

Key words: colitis, dysplasia, colonic carcinogenesis, rats.

Streszczenie

Wprowadzenie. Badania dotyczą zwierzęcego modelu przewlekłego zapalenia okrężnicy odpowiadającego ludzkiemu wrzodziejącemu zapaleniu jelita grubego. Poglądy na temat karcynogenezy u pacjentów z zapalnymi chorobami jelit są dotychczas nieustalone i kontrowersyjne.

Cel pracy. Zbadanie karcynogenezy na eksperymentalnym modelu zapalenia jelita grubego u szczura.

Materiał i metody. Do badań użyto 50 2-miesięcznych szczurów szczepu Wistar. Doświadczenie podzielono na dwa etapy. Pierwszy to indukcja zapalenia jelita grubego przez doodbytnicze podanie kwasu octowego, a drugi to karcynogeneza wywołana dootrzewnowym podaniem azoksymetanu: w pierwszej grupie przy zmienionym zapaleniu jelicie, w drugiej przy jelicie zdrowym. Metodą immunohistochemiczną oceniono p53 i Ki67. Dodatkowo uwzględniono zmiany o charakterze dysplazji (*low and high grade*). Oceniono także tkankę wątrobową pod względem zmian o charakterze przerzutowym.

Wyniki. W obu grupach poddanych działaniu karcynogenu nowotwory rozwinęły się odpowiednio w 30 i 20% (o 10% częściej w grupie zwierząt cierpiących na zapalenie okrężnicy). Zmiany histopatologiczne (dysplazja *high and low grade*) wyprzedzały rozwój nowotworu. Reakcje Ki67 i p53 były dodatnie w zmianach dysplastycznych (*high grade*) i nowotworowych. U zwierząt z przewlekłym procesem zapalnym w jelicie dodatkowo wystąpiły zmiany o charakterze przerzutowym do wątroby.

Wnioski. Przewlekły proces zapalny o charakterze *colitis*, odpowiadający wrzodziejącemu zapaleniu okrężnicy u ludzi, pobudza rozwój raka jelita grubego. W grupie zwierząt chorych na zapalenie okrężnicy proces ten jest częstszy i bardziej ekspansywny (*Adv Clin Exp Med* 2006, 15, 6, 983–988).

Słowa kluczowe: zapalenie okrężnicy, dysplazja, karcynogeneza, szczury.

Ulcerative colitis is known to be a predisposing factor to colonic cancer. It develops in 1% of patients per year after 10 years of disease. The sequence of chronic inflammation, dysplasia, and subsequent colonic cancer is commonly accepted as the underlying pathomechanism [1, 2]. However, the magnitude of the risk and accurate assessment still remains controversial. Dysplasia has been used as a marker for the subsequent development of colorectal cancer. The presence of high- or low-grade dysplasia is indicative of a high risk for carcinoma [3]. Alternative markers that enable the detection of premalignant lesions are also used. The p53 tumor suppressor gene is inactivated in colonic neoplasms; this appears as an early event in the development of malignancy [4]. Ki67 immunoreactivity, which is a marker of cell proliferation, also occurs in dysplastic epithelium. It is useful to distinguish dysplastic from regenerative mucosa, especially when the colon is actively inflamed [5]. Furthermore, the evaluation of liver tissue involvement is essential in connection with metastases to the liver

as an indicator of poor prognosis and a dynamic factor in neoplastic disease [6].

Considering the above, the aim of this study was to establish an experimental model of chronic colitis and carcinogenesis to investigate the relationship between inflammation and cancer development. Sequential alterations in p53 expression and the cell-proliferation antigen Ki67 were also studied. The degree of dysplasia (high and low grade) was evaluated as well as the affection of liver tissue.

Material and Methods

Fifty Wistar rats of both sexes, two months old and weighing 150–210 g, bred in the Department of Pathological Anatomy, Silesian Piasts University of Medicine in Wrocław, were used for the 31-week experiment. They were divided into 5 groups of 10 animals (5 male and 5 female) each. Three of the groups were experimental and two were controls (Table 1). All the animals were

Table 1. Experimental design

Tabela 1. Plan doświadczenia

Group (Grupa)	Procedure (Zabieg)	No. of animals (Liczba zwierząt)
I experimental (I Badana)	colitis induction (4% acetic acid instillation)	10
II experimental (II Badana)	carcinogen (AOM) administration	10
III experimental (III Badana)	colitis induction, then carcinogen administration	10
I control (I Kontrolna)	normal saline administration to the rectum	10
II control (II Kontrolna)	normal saline intraperitoneal administration	10
Group (Grupa)	weeks	
	1 2 3 4 5 6 7 8 9 10 11 12 13 14 15 16 17 18 19 20 21 22 23 24 25 26 27 28 29 30 31	
I Experimental (I Badana)		
II Experimental (II Badana)		
III Experimental (III Badana)		
I Control (I Kontrolna)		
II Control (II Kontrolna)		

	4% acetic acid (4% kwas octowy)
	azoxymethane (AOM) (azoksymetan)
	normal saline (NaCl)

housed individually in plastic cages (up to 5 animals) and fed with a standard Labofeed H diet (produced by Morawski, Kcynia, Poland) every other day and water *ad libitum*. The room temperature (21–22°C) and humidity (62–65%) were automatically controlled. All invasive procedures were performed under Bioketan (Biowet, Poland) anesthesia (3 mg/kg body weight). The study consisted of the following stages.

1. Chronic colitis induction in the experimental groups I and III by six standardized weekly instillations of 4% acetic acid performed through a rectal cannula 2 cm proximally to the anus. The initial dose of 2 ml of acetic acid was halved in the subsequent injections to maintain the inflammatory process in the rectum and distal colon [7]. Saline solution was used in the control groups.

2. Carcinogenesis. Azoxymethane (AOM, Sigma Aldrich, A-9517, USA) was used as the carcinogen, similarly to other trials [8–10]. The dose was 15 mg/kg body weight in six weekly intraperitoneal injections. In experimental group II, only AOM was given (i.e. without prior induction of chronic colitis). In experimental group III, colitis was first induced and then the carcinogen was given. Saline solution was used in the control groups (Table 1).

3. Macro- and microscopical examination. The animals in the experimental and control groups were kept alive for 31 weeks, when the animals were sacrificed (under Bioketan anesthesia). The colon and liver were investigated and dysplastic lesions were evaluated. Specimens were stained with hematoxylin and eosin (HE).

4. Immunohistochemistry was also performed using rat monoclonal antibodies against p53 (NCL-p53-CM1) and Ki67 (RTU-Ki67-MM1) antigen (Novocastra Laboratories, United Kingdom). Both colon and liver tissue were evaluated.

The design of the experiment is shown in Table 1.

Results

The results are shown in Table 2. Twenty-five weeks after the last injection of carcinogen in experimental group III, in which chronic colitis had first been induced, affection of the mesenteric lymph nodes (Fig. 1) was noted. In 100% (10) of the animals, low (30%, 3 animals), high (30%, 3 animals), or both high and low (40%, 4 animals) dysplasia was observed (Figs. 2 and 3). Colonic

Table 2. Results of experimental carcinogenesis after colitis induction (number of animals)

Tabela 2. Wyniki doświadczalnej karcynogenezy na modelu zapalenia okrężnicy (liczba zwierząt)

Dysplastic lesions – group (Zmiany dysplastyczne – grupa)	High grade (Wysoki stopień) % (n)	Low grade (Niski stopień) % (n)	High and low grade (Wysoki i niski stopień) % (n)
I experimental (I Badana)	0 (0)	0 (0)	0 (0)
II experimental (II Badana)	0 (0)	60 (6)	40 (4)
III experimental (III Badana)	30 (3)	30 (3)	40 (4)
Carcinoma lesions (Zmiany nowotworowe)	colon		liver
I experimental (I Badana)	chronic colitis		
II experimental (II Badana)	20% (2)		0% (0)
III experimental (III Badana)	30% (3)		20% carcinoma (2) 10% steatosis (1)
Immunohistochemistry p53, Ki67, and carcinoma lesions (Ocena immunohistochemiczna p53 i Ki67 oraz zmiany nowotworowe)	colon		liver
I Experimental (I Badana)	chronic colitis		0% positive
II Experimental (II Badana)	20% positive		0% positive
III Experimental (III Badana)	30% positive		20% positive

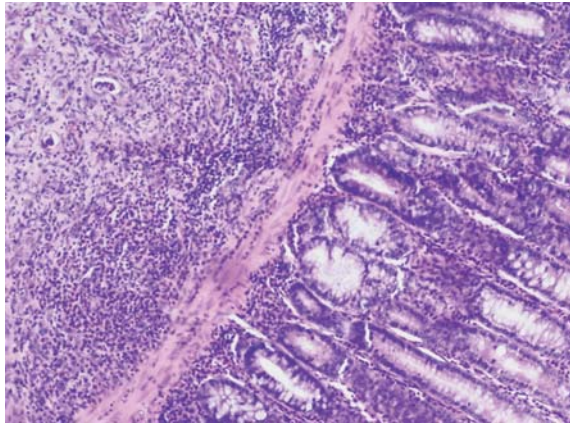


Fig. 1. Chronic colitis, HE, $\times 100$

Ryc. 1. Przewlekłe zapalenie okrężnicy, HE, powiększenie 100 \times

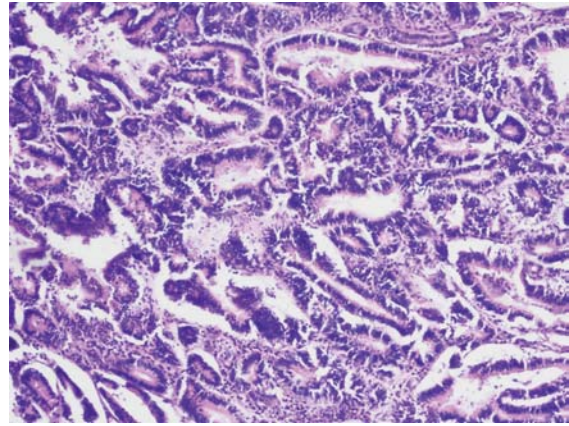


Fig. 4. Colonic adenocarcinoma, HE, $\times 100$

Ryc. 4. Adenocarcinoma – okrężnica, HE, powiększenie 100 \times

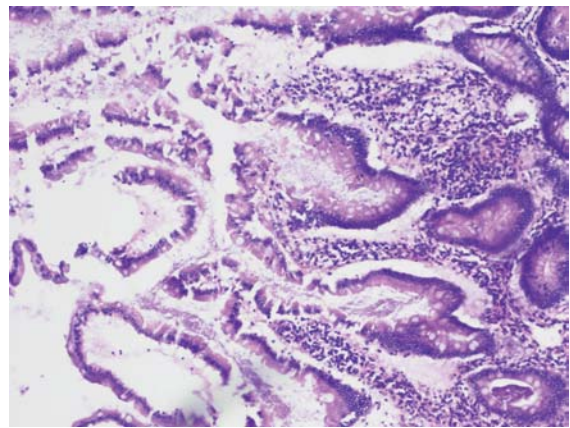


Fig. 2. Low-grade dysplasia, HE, $\times 100$

Ryc. 2. Dysplazja niskiego stopnia, HE, powiększenie 100 \times

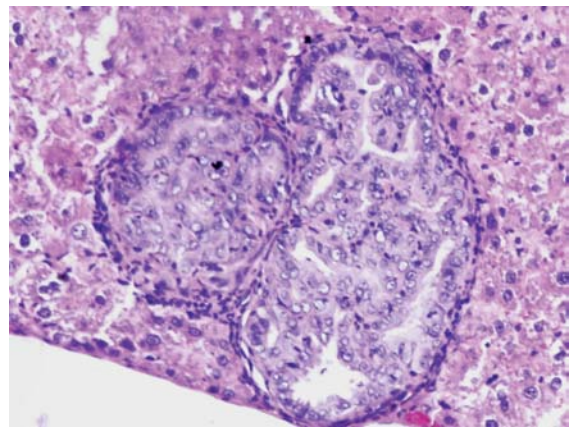


Fig. 5. Liver metastatic adenocarcinoma, HE, $\times 210$

Ryc. 5. Adenocarcinoma – przerzut do wątroby, HE, powiększenie 210 \times

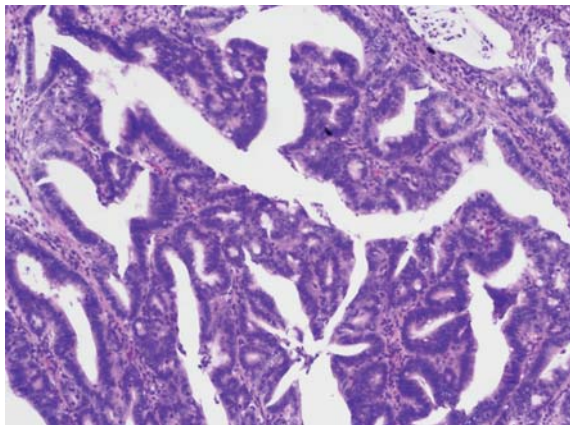


Fig. 3. High-grade dysplasia, HE, $\times 100$

Ryc. 3. Dysplazja wysokiego stopnia, HE, powiększenie 100 \times

adenocarcinoma developed in three animals (30%) of this group (Fig. 4). The rectum and descending colon were affected. Two (20%, 2 animals) or three (10%, 1 animal) tumors were observed

simultaneously. All tumors were preceded by dysplasia. Additionally, metastatic adenocarcinoma (20%, 2 animals, Fig. 5) and steatosis of the liver tissue (10%, 1 animal) coexisted with colonic adenocarcinoma. Immunohistochemical investigation of p53 and Ki67 antigen showed positive reaction in dysplastic (mostly high grade) lesions (Figs. 6 and 7), carcinoma lesions of the colon, and in liver tissue (Figs. 8 and 9).

In experimental group II, treated with carcinogen only, all animals developed dysplasia. Six animals (60%) showed low-grade dysplasia and the other 40% (4 animals) both low- and high-grade dysplasia. Twenty percent (2 animals) in this group suffered from colonic adenocarcinoma. Two tumors were observed simultaneously in the rectum and descending colon. The liver tissue was unchanged. Immunohistochemistry of p53 and Ki67 antigen showed positive reaction in dysplasia and carcinoma lesions of the colon.

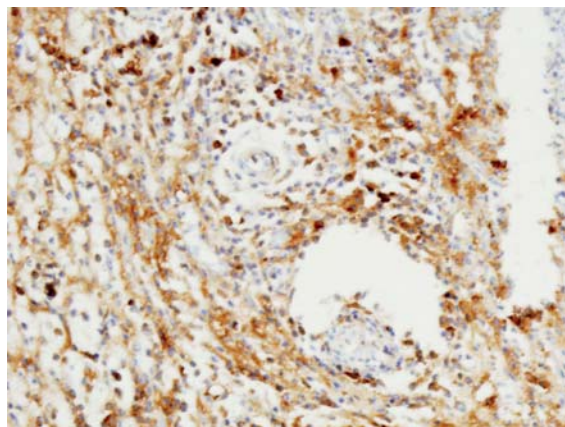


Fig. 6. Ki67 in high-grade dysplasia, $\times 210$

Ryc. 6. Ki67 w zmianach o charakterze dysplazji wysokiego stopnia, powiększenie 210 \times

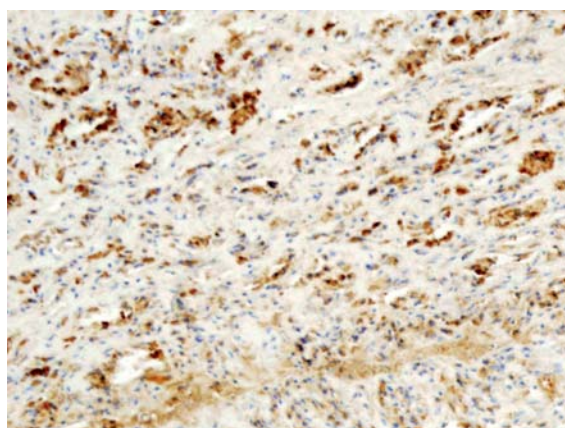


Fig. 7. p53 in high-grade dysplasia, $\times 210$

Ryc. 7. p53 w zmianach o charakterze dysplazji wysokiego stopnia, powiększenie 210 \times

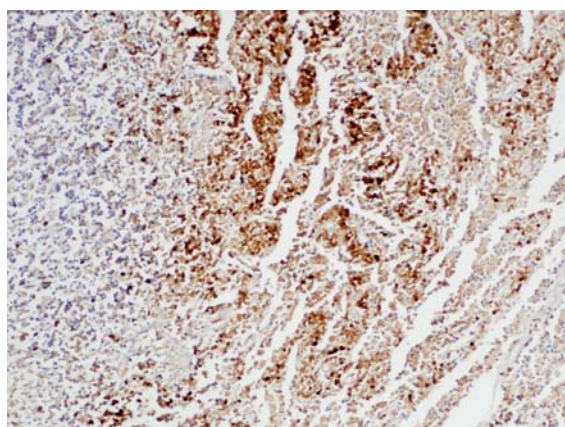


Fig. 8. Ki67 in colonic adenocarcinoma, $\times 100$

Ryc. 8. Ki67 w raku okrężnicy, powiększenie 100 \times

Discussion

As is shown in the references, patients with chronic ulcerative colitis are at increased risk (8%) of developing colorectal carcinoma, particularly if

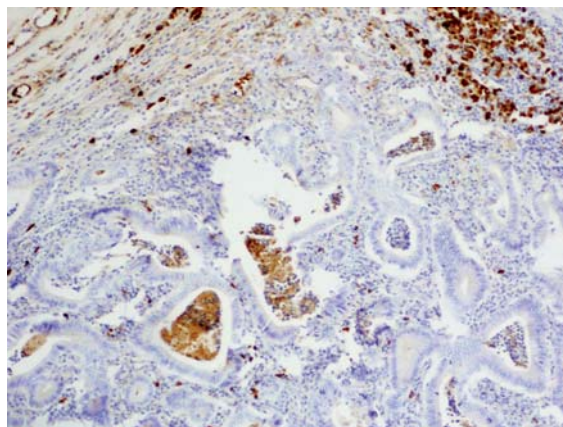


Fig. 9. p53 in colonic adenocarcinoma, $\times 100$

Ryc. 9. p53 w raku okrężnicy, powiększenie 100 \times

there is long-standing disease or extensive colitis [11–13]. The most significant predictor of the risk of malignancy is the presence of dysplasia in colonic biopsies [14]. When dysplasia develops in ulcerative colitis it is often widespread and multifocal, suggesting that neoplastic transformation in this condition may result from abnormalities occurring over large regions of the colonic mucosa [3].

In the present study, adenocarcinoma of the colon developed in 30% of animals suffering from induced chronic colitis. The development of carcinoma was preceded by dysplasia, mostly high grade in colitis-affected intestine. Colitis was conducive to the dysplasia-carcinoma sequence. Abnormal and persistent epithelial hyperproliferation could be causally related to the development of colorectal cancers in the setting of chronic colitis inflammation [5, 6].

The biomarkers of cell proliferation (Ki67) and gene expression (p53) are used in studies to assess the malignant lesions of colonic mucosa [8, 14]. In experimental studies, both Ki67 and p53 were positive as an early event of malignancy [4]. Additionally, liver metastases from colonic cancer is a challenging problem, associated with poor prognosis and as a dynamic factor [15, 16]. In this experiment, metastases to the liver were observed only in the animals with induced chronic colitis. The process of carcinogenesis was more expansive (high-grade dysplasia, positive expressions of Ki67 and p53) in this group, similar to colorectal carcinoma complicating ulcerative colitis in humans [17, 18].

In conclusion, these findings suggest that chronic colitis predisposes or even leads to the development of colonic adenocarcinoma and that the process of carcinogenesis is more dynamic and expansive in rats suffering from colitis than in healthy animals.

Acknowledgments. The authors wish to express their sincere gratitude to Professor Bożenna Zawirska from the Department of Pathology, Silesian Piasts University of Medicine in Wrocław, for consultation of the histological sections. They also thank Dr. Agnieszka Halań for providing microphotographs.

References

- [1] **Munkholm P:** Review article: the incidence and prevalence of colorectal cancer in inflammatory bowel disease. *Aliment Pharmacol Ther* 2003, 18, 2, 1–5.
- [2] **Lashner BA, Provencher KS, Bozdech JM, Brzeziński A:** Worsening risk for the development of dysplasia or cancer in patients with chronic ulcerative colitis. *Am J Gastroenterol* 1995, 30, 377–380.
- [3] **Ishitsuka T, Kashiwagi H, Konishi F:** Microsatellite instability in inflamed and neoplastic epithelium in ulcerative colitis. *J Clin Pathol* 2001, 154, 526–533.
- [4] **Yin J, Harpaz N, Tong Y, Huang Y, Laurin J, Greenwald BD, Hontanosas M, Newkirk C, Meltzer SJ:** P53 point mutations in dysplastic and cancerous ulcerative colitis lesions. *Gastroenterology* 1993, 104, 1633–1639.
- [5] **Vetuschi A:** Increased proliferation and apoptosis of colonic epithelial cells in dextran sulfate sodium-induced colitis in rats. *Dig Dis Sci* 2002, 47, 1447–1457.
- [6] **Bansal P, Sonnenberg A:** Risk factors of colorectal cancer in inflammatory bowel disease. *Am J Gastroenterol* 1966, 91, 44–48.
- [7] **Elson ChO, Sartor RB, Tennyson GS, Ridell RH:** Experimental models of inflammatory bowel disease. *Gastroenterology* 1995, 109, 1344–1367.
- [8] **Iseki K, Tatsuta M, Uehara H, Iishi H, Yano H, Sakai N, Ishiguro S:** Inhibition of angiogenesis as a mechanism for inhibition by 1 alpha-hydroxyvitamin D₃ and 1,25-dihydroxyvitamin D₃ of colon carcinogenesis induced by azoxymethane in Wistar rats. *Int J Cancer* 1999, 81, 730–733.
- [9] **Matthews J, Cooke T:** Changes in crypt cell DNA content during experimental colonic carcinogenesis. *Br J Cancer* 1986, 53, 787–791.
- [10] **McCue JL, Sheffield JP, Uff C, Philips RK:** Experimental carcinogenesis at sutured and sutureless colonic anastomoses. *Dis Colon Rectum* 1992, 35, 902–909.
- [11] **Gillen CD, Walmsley RS, Prior P, Andrews HA, Allan RN:** Ulcerative colitis and Crohn's disease: a comparison of the colorectal cancer risk in extensive colitis. *Gut* 1994, 35, 1590–1592.
- [12] **Langholz E, Munkholm P, Dawidsen M, Binder V:** Colorectal cancer risk and mortality in patients with ulcerative colitis. *Gastroenterology* 1993, 104(4), 1241–1242.
- [13] **Winther KV, Jess T, Langholtz E, Mungholm P, Binder V:** Survival and cause-specific mortality in ulcerative colitis: follow up of a population-based cohort in Copenhagen County. *Gastroenterology* 2003, 125(6), 1881–1883.
- [14] **Solomon MJ, Schnitzel M:** Cancer and inflammatory bowel disease: bias, epidemiology, surveillance and treatment. *World J Surg* 1998, 22, 352–358.
- [15] **Pasz-Walczak G, Szybka M, Kordek R:** Comparative analysis of microsatellite instability and expression of MLH1, MSH2, P21(WAF1), P53 proteins in colorectal cancer and estimation of their clinico-pathological significance. *Pol J Pathol* 2004, 2, 39.
- [16] **Leslie A, Carey FA, Pratt NR, Steele RJC:** The colorectal adenoma-carcinoma sequence. *Br J Surg* 2002, 89, 845–860.
- [17] **Heushen UA, Heuschen G, Autsbach F, Allemeyer EH, Herfarth C:** Adenocarcinoma in the ileal pouch: late risk of cancer after restorative proctocolectomy. *Int J Colorectal Dis* 2001, 16, 126–130.
- [18] **Conell WR, Talbot IC, Harpaz N, Britto N, Wilkonson KH, Kamm MA, Lennard-Jones JE:** Clinicopathological characteristic of colorectal carcinoma complicating ulcerative colitis. *Gut* 1994, 35, 1419–1423.

Address for correspondence:

Romualda Wojczys
1st Department of General, Gastroenterological, and Endocrine Surgery,
Silesian Piasts University of Medicine
ul. Poniatowskiego 2,
50-326 Wrocław
Poland
Tel.: +48 71 321 51 70
e-mail: rwojczys@chir.am.wroc.pl

Conflict of interest: None declared

Received: 20.04.2006 r.

Revised: 3.10.2006 r.

Accepted: 9.11.2006 r.

Praca wpłynęła do Redakcji: 20.04.2006

Po recenzji: 3.10.2006

Zaakceptowano do druku: 9.11.2006